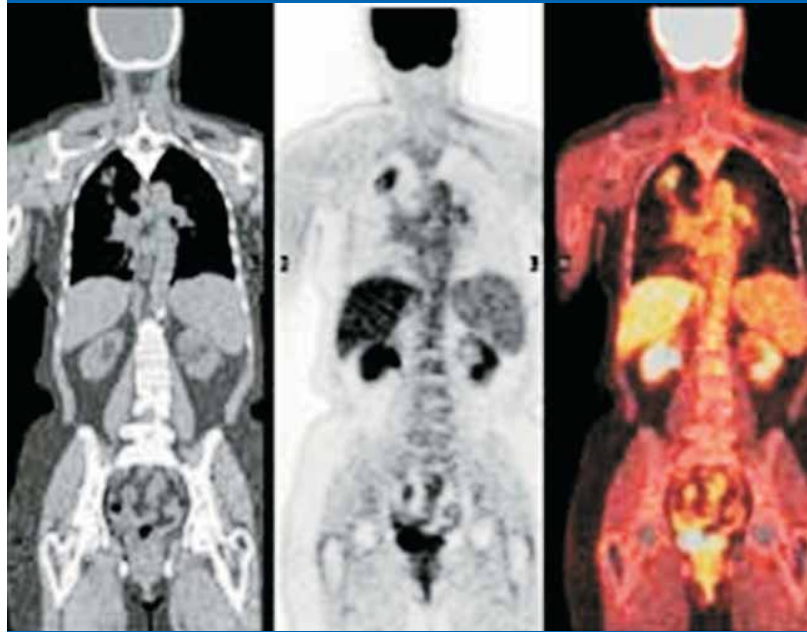


EKO X-RAY & IMAGING INSTITUTE



PET

POSITRON EMISSION TOMOGRAPHY



CT

PET

PET/CT

PET-CT

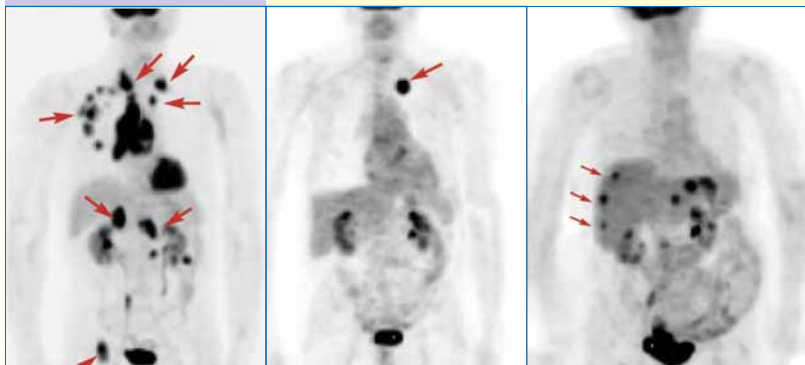
FROM RESEARCH ARENA TO ROUTINE PRACTICE
A NEW ERA BEGINS IN MEDICAL IMAGING

54, Jawaharlal Nehru Road Kolkata - 700 071



Positron Emission Tomography provides biochemical & metabolic information of different organ systems & disease process. This level of functional & molecular information is not obtained from other modalities.

The Anatomic Resolution of PET is poor. Fusion of PET with CT images gives complete structural & functional information. That is PET-CT.



PET is the only metabolic tool powerful enough to accurately image and measure the metabolic function of cancer.

PET differentiates scar tissue and a tumor.

PET save patients from unnecessary surgery, and often the family from the emotional trauma of further diagnostic evaluation.

Cancer is one of the major causes of death worldwide.

PET reveals metastatic disease other imaging techniques simply can't detect.

PET helps to diagnose cancer and guides physicians to the most beneficial therapies

PET-CT Indications

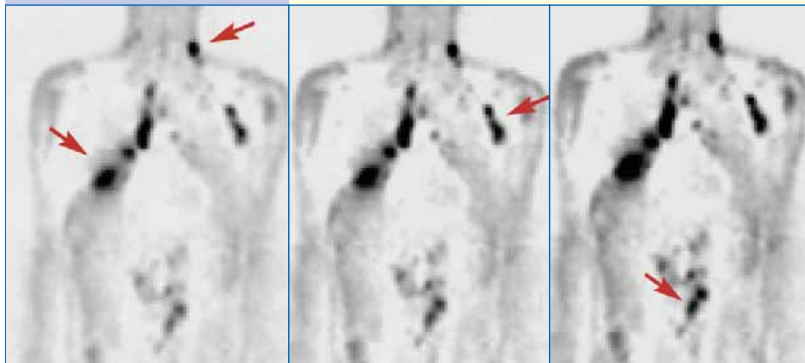
ONCOLOGY

- Early Diagnosis
- Staging & Restaging
- Treatment Planning
- Evaluation of Therapy
- Detection of Recurrence
- Assessment of Prognosis

The commonest cancers where PET/CT has a major role to play

- Solitary Pulmonary (Nodule (SPN))
- Lung Cancer
- Colorectal carcinoma
- Breast Cancer
- Lymphoma
- Head and Neck Cancer
- Malignant Melanoma
- Gastric & Esophageal Cancer
- Bone Tumors
- Ovarian Cancer
- Gastrointestinal Tumors
- Urological Malignancies
- Neuroendocrine Tumors
- Pheochromocytomas and Paragangliomas
- Carcinoid Tumors
- Adrenocortical Tumors
- Pituitary Tumors
- Brain Tumors

Is the tumor benign or malignant ?

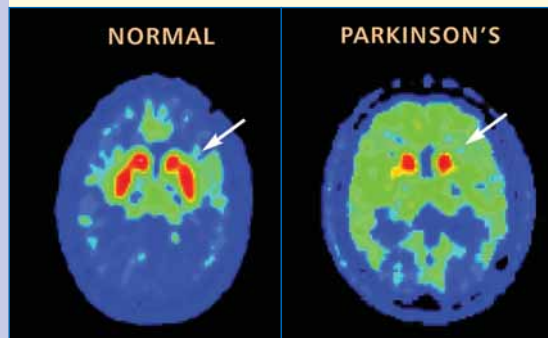
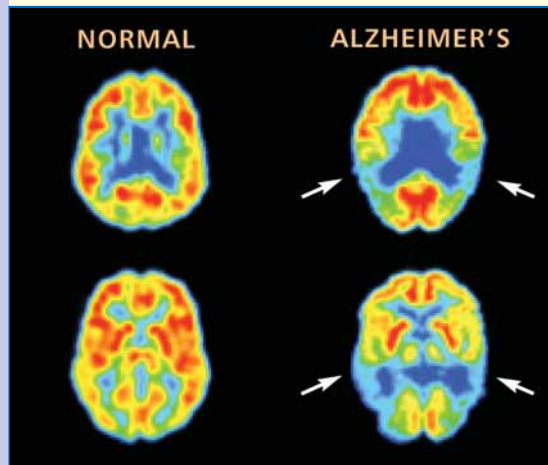


Where is the tumor?

PET-CT Indications

NEUROLOGY

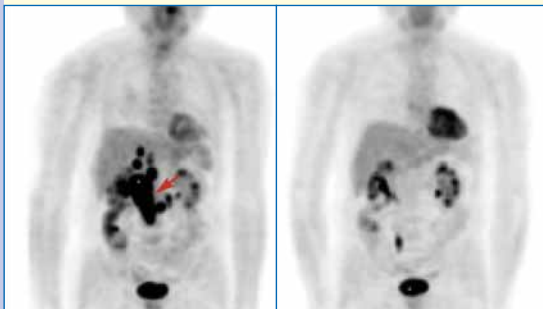
- Detection of Epileptic Focus
- Alzheimer's Disease
- Parkinsonism
- Evaluation of Brain Tumour



Pre-chemotherapy, staging PET, March, 2000

Post-chemotherapy, PET, July 2000

Is my treatment working?



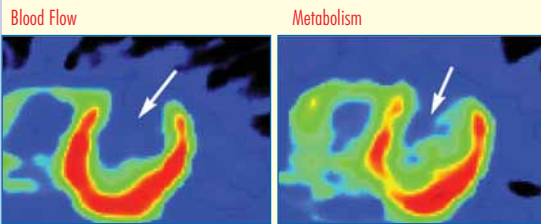
Update: This patient underwent chemotherapy and the subsequent PET scan showed no evidence of disease.

PET-CT Indications

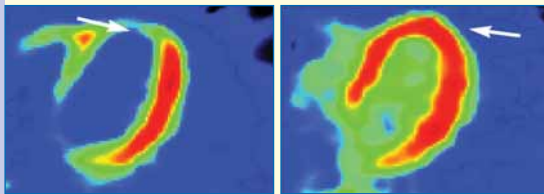
CARDIOLOGY

- Assessment of Viability
- Evaluation of IHD
- Planning of Transplant

Patient 1
Transplant




Patient 2
Bypass



PET is the gold standard to determine the viability of heart tissue for revascularization.

Rest



Stress

- Coronary Artery Disease
- Cardiac Transplantation
- Bypass Surgery

PET-CT Indications

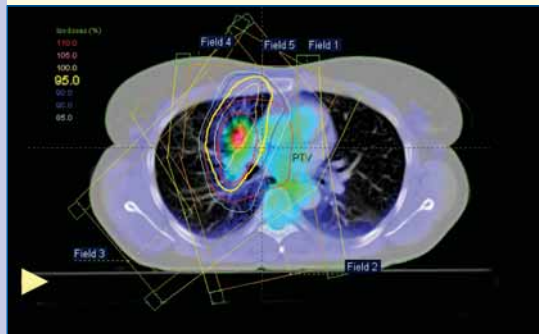
RT-PLANNING & RESPONSE

Case: Female with bronchial Ca for Radio Therapy Planning (RTP).

Findings: Evaluate extent of disease prior to RT.

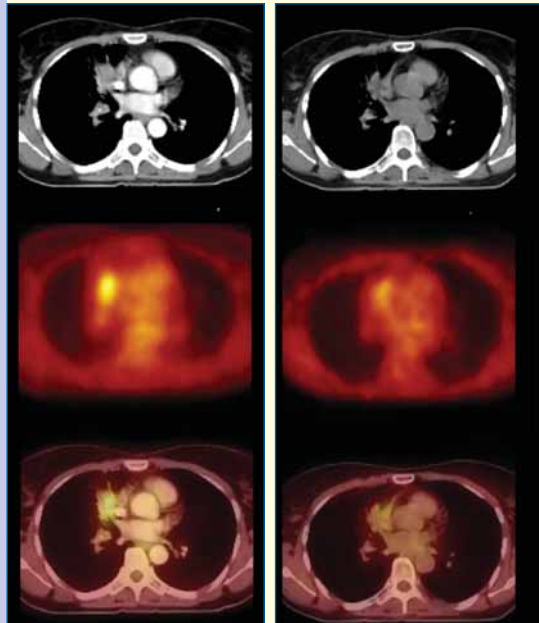
RT planning based CT or PET/CT. Evaluate RT response.

Treatment plan



Pre-treatment

Post-treatment



Other uses of PET-CT

- Sarcoidosis
- Infection Imaging
- Pyrexia of Unknown Origin

PET Facts

In a world of limited resources, PET saves time, saves money, and, most importantly, saves lives.

PET is safe.

PET can tell whether a tumor is benign or cancerous.

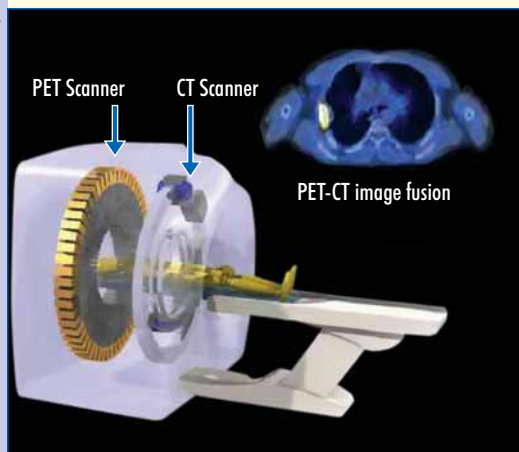
PET shows all the organ systems of the body in a single exam, so it can indicate whether or not cancer has spread.

PET diagnoses disease often before it shows up on other tests.

PET shows the progress of disease and how the body responds to treatment.

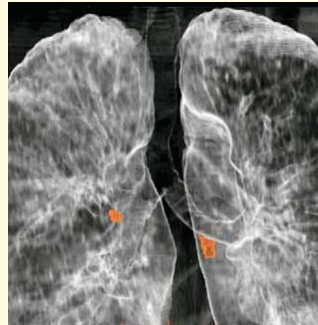New, combined PET/CT scanners provide physicians with both anatomical and molecular images in the same test.

PET-CT Scanner



CLINICAL APPLICATION OF PET-CT

- Tumor diagnosis
- Benign or Malignant
- Detection of Metastasis
- Degree of Malignancy
- Biopsy guidance
- Staging
- Therapy planning
- Prognosis assessment
- Tumor persistence
- Therapy response monitoring
- Differentiating recurrence from necrosis



EKO X-RAY & IMAGING INSTITUTE

54, Jawaharlal Nehru Road Kolkata-700 071

Phone: 22828100/05/06/09

Fax: 22828098

E-mail: enquiry@ekoxray.com

Web: www.ekoxray.com